

# Reoperation for Early Failure of a Freestyle Bioprosthesis Using a Full Root Technique

Aki Kitamura<sup>1</sup>, Nobuhiro Handa<sup>1</sup>, Yu Shomura<sup>1</sup>, Hidetaka Wakiyama<sup>1</sup>, Masahiko Shinka<sup>1</sup>, Hiroshi Fujiwara<sup>1</sup>, Michihiro Nasu<sup>1</sup>, Kazuaki Tanabe<sup>2</sup>, Tomoko Tani<sup>2</sup>, Shigefumi Morioka<sup>2</sup>, Yukikatsu Okada<sup>1</sup>

*Departments of Thoracic Cardiovascular Surgery and <sup>2</sup>Cardiology, Kobe General Hospital, Kobe, Japan*

The case is reported of a 65-year-old male who required reoperation for early failure of a Freestyle stentless valve aortic root bioprosthesis implanted using the full root technique. The bioprosthesis had been implanted to treat annuloaortic ectasia associated with severe aortic regurgitation (AR). At 18 months postoperatively, a new diastolic murmur developed, though without complaint by the patient. Transthoracic echocardiography demonstrated severe AR with aneurysmal dilatation of the non-coronary porcine sinus of Valsalva. Pseudoaneurysm forma-

tion, associated with perforation of the non-coronary sinus of Valsalva of the bioprosthesis, was observed at surgery. On inspection, the pseudoaneurysm had pushed the commissures inward, and had created severe aortic valve regurgitation. No infection or calcification was detected on the Freestyle valve, and the aortic root was successfully reconstructed using a composite graft.

The Journal of Heart Valve Disease 2007;16:275-277

The Freestyle aortic bioprosthesis (Medtronic Inc., Minneapolis, MN, USA) has been shown to possess potential advantages over conventional stented bioprosthetic valves in terms of a lower transvalvular pressure gradient and a wide choice of implantation techniques. Consequently, this valve has been more frequently applied for elderly patients with aortic valve and aortic root disease. Most often, one of four techniques is used to implant the Freestyle bioprosthesis, on the basis of the anatomic features. Herein is reported a surgical case which required reoperation 18 months after a full root replacement using the Freestyle bioprosthesis for annuloaortic ectasia.

## Case report

A 65-year-old male underwent aortic root replacement for moderate to severe aortic regurgitation (AR) associated with annuloaortic ectasia (AAE) using a Freestyle stentless aortic root bioprosthesis (27 mm) and a full root technique. Previous preoperative echocardiography had identified a left ventricular end-diastolic diameter (LVEDD) of 67 mm, a left ventricu-

lar end-systolic diameter (LVESD) of 52 mm, an aortic sinus of Valsalva diameter of 51 mm, and a left ventricular ejection fraction (LVEF) of 52%. Thus, a full root technique, using a Freestyle bioprosthesis, was selected for this patient.

At six months after surgery, echocardiography demonstrated an absence of AR with LVEDD of 43 mm, LVESD of 27 mm, and LVEF of 58%. No evidence was seen of any cardiac dilatation or AR, and the left ventricular function was normal. The postoperative course was uneventful, and there was no echocardiographic evidence of any a false aneurysm close to the Freestyle valve during a six-month follow up.

At 18 months postoperatively, however, a new diastolic cardiac murmur developed, though without complaint from the patient. Transthoracic echocardiography demonstrated the presence of severe AR with aneurysmal change at the non-coronary sinus of Valsalva of the porcine stentless valve. Color-flow imaging demonstrated flow between the non-coronary sinus and the false aneurysm (Fig. 1), and the LVEDD and LVESD were remarkably enlarged, to 59 mm and 46 mm, respectively. Aortography confirmed the presence of a huge pseudoaneurysm at the non-coronary sinus of Valsalva of the Freestyle bioprosthesis.

At reoperation, a large perforation of the non-coronary sinus of the Freestyle bioprosthesis was observed, though without infection or calcification (Fig. 2). The sizes of the false aneurysm and the perforation were

---

Address for correspondence:  
Yukikatsu Okada MD, 4-6 Minatojima, Nakamachi, Chuo-ku, Kobe,  
Japan 650-0046  
e-mail: yukiok@kcgh.gr.jp

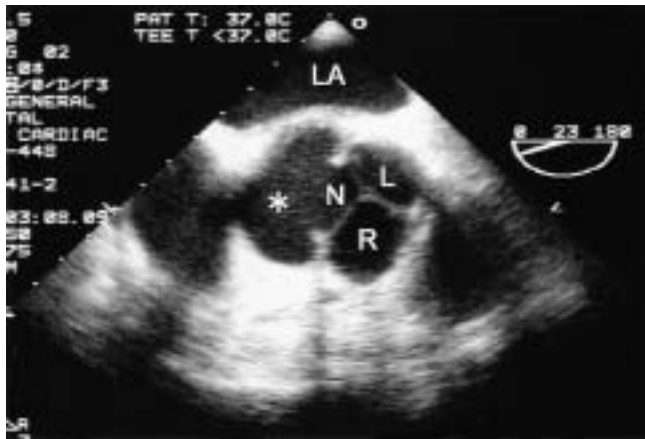


Figure 1: Transesophageal basal short-axis echocardiogram at the level of the Freestyle bioprosthesis, showing the false aneurysm (\*) and perforation of the non-coronary sinus of the bioprosthesis.




Figure 2: Aortic view of the Freestyle bioprosthesis, showing perforation of the non-coronary sinus, and false aneurysm outside the non-coronary sinus. LCC: Left coronary cusp; NCC: Non-coronary cusp; RCC: Right coronary cusp.

4.0×2.0 cm and 0.5×0.5 cm, respectively. The false aneurysm had pushed the commissures inwards and created severe AR. The operative findings of the Freestyle bioprosthesis showed three flexible leaflets, but the commissures were all intact. Thus, the AR had not been caused by valve failure but rather by valve deformation associated with the hematoma.

Following generous and complete removal of the Freestyle bioprosthesis, leaving the right and left coronary buttons intact, the aortic root was reconstructed with a composite graft using a 28-mm tube graft (Gelseal, Vascutek, UK) and a 25-mm bovine pericardial bioprosthesis (Edwards Lifesciences, CA, USA).

Histological examination of the explanted Freestyle valve showed the presence of inflammatory cells and the growth of fibrocytes in the connective tissue, as normally seen in an explanted bioprosthesis. There were no remarkable findings of infection. The patient had an uneventful recovery and was discharged from hospital two weeks after surgery. Currently, he is doing well, with no abnormal findings having been detected at four years after reoperation.

## Discussion

While the need to perform early redo surgery following a full root technique with the Freestyle stentless aortic root bioprosthesis is a rare occurrence (1,2), the present patient developed severe AR at only 18 months after the initial surgery. Intraoperatively, a huge pseudoaneurysm secondary to perforation of the porcine non-coronary sinus was seen to be pushing the commissures of the Freestyle bioprosthesis inwards. This led to valve incompetence and a loss in leaflet coaptation, such that severe AR occurred.

The perforation associated with the hematoma outside the sinus might have gradually increased, without symptoms, during the 18-month postoperative period. A microscopic examination of the excised valve showed a well-healed fibrous wall of a false aneurysm, but no signs of any specific infection. With regards to this particular type of structural valve deterioration, three factors are worthy of mention, namely the prosthesis, the surgical procedure employed, and the patient.

In the aortic root, collagenous structures gradually replace the aortic elastic tissue from the level of the sinotubular junction towards the annulus (3). The wall of the sinus of Valsalva is thin and fragile compared to the aortic wall; furthermore, a non-coronary cusp would suffer greater hemodynamic stress due to the lack of a coronary orifice. Attention has also been directed at the hemodynamics of aortic flow. For example, Nygaard et al. (4) demonstrated aortic flow as being eccentric, while Kleine et al. (5) noted that the eccentric flow was associated with maximum speed and flow volume through the non-coronary cusp. Therefore, if a weak tissue structure at the non-coronary cusp can be demonstrated histologically, anatomically, and hemodynamically, then there may be a risk of rupture under high wall stress. Virtually all reports of perforation of the Freestyle valve were in the non-coronary sinus (6).

Operative manipulation should also be considered as an etiological factor for the bioprosthesis failure, as a degree of trauma might have been inflicted intraoperatively on the non-coronary sinus, between the ini-

tial rinsing of the Freestyle valve and the completion of implantation. As the perforation did not connect the distal suture line or suture lines of the coronary buttons, the surgical instruments used to hold the Freestyle valve may have caused minor trauma, but without bleeding. Consequently, during surgery the present authors rinsed and held the valve only with the fingers. Thus, although valve failure was considered to have been caused by the above-mentioned multiple factors, the actual reason was unclear.

Only one other report of Freestyle bioprosthesis failure using a full root technique for AR associated with AAE was identified, and this case was also asymptomatic (6).

In conclusion, a strict, long-term follow up is mandatory for surgical cases in which the Freestyle stentless valve is used.

#### References

1. Kajiwaru T, Imoto Y, Sakamoto M, et al. Primary tissue failure of the freestyle stentless aortic root bioprosthesis. *Jpn J Thorac Cardiovasc Surg* 2003;51:333-335
2. Takami Y, Ina H. Resolution of perivalvular hematoma of the freestyle stentless aortic root bioprosthesis implanted with a subcoronary technique. *Jpn J Thorac Cardiovasc Surg* 2001;49:675-678
3. Sutton JP, III, Ho SY, Anderson RH. The forgotten interleaflet triangles: A review of the surgical anatomy of the aortic valve. *Ann Thorac Surg* 1995;59:419-427
4. Nygaard H, Paulsen PK, Hasenkam JM, Kromann-Hansen O, Pedersen EM, Rovsing PE. Quantitation of the turbulent stress distribution downstream of normal, diseased and artificial aortic valves. *Eur J Cardiothorac Surg* 1992;6:609-617
5. Kleine P, Klesius AA, Scherer M, Abdel-Rahman U, Moritz A. Initial in vivo results of the new Medtronic Advantage bileaflet valve in aortic position and comparison to the SJM. *Cardiovasc Surg* 2002;10:494-499
6. Kameda Y, Mizuguchi K, Kuwata T, et al. Aortopulmonary fistula due to perforation of the aortic wall of a Freestyle stentless valve. *Ann Thorac Surg* 2004;78:1827-1829